

Anatomy Review: Urinary System

Graphics are used with permission of:
adam.com (<http://www.adam.com/>)
Benjamin Cummings Publishing Co (<http://www.aw.com/bc>)

Page 1. Introduction

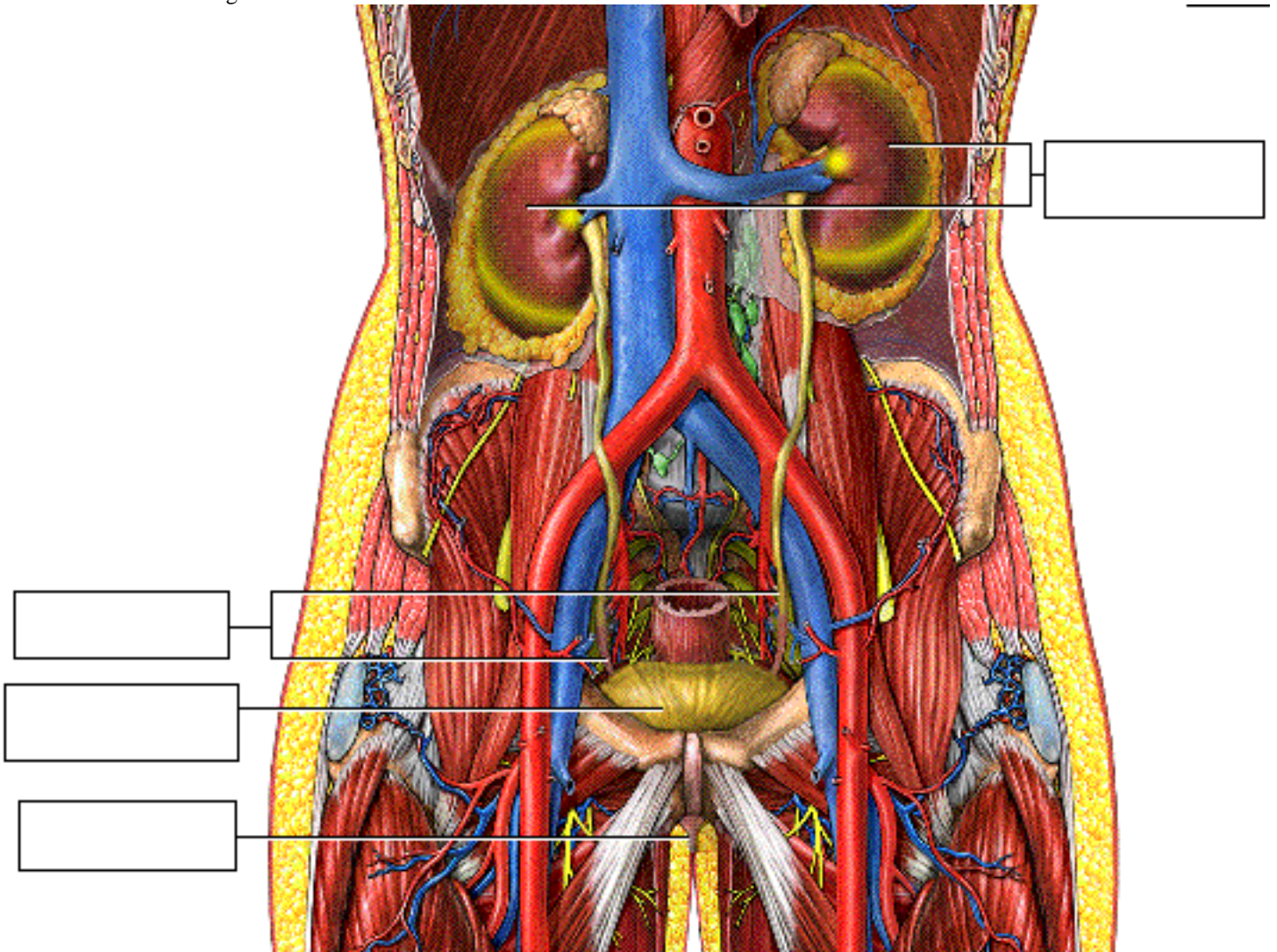
- The urinary system rids the body of waste materials and controls the volume and composition of body fluids.
- Highly specialized cells in the kidneys are essential to these processes.

Page 2. Goals

- To review the anatomy of the urinary system, particularly the kidney
- To examine the vascular and tubular portions of the nephron
- To compare and contrast the specialized cells of the tubular epithelium
- To review the unique structure of the juxtaglomerular apparatus

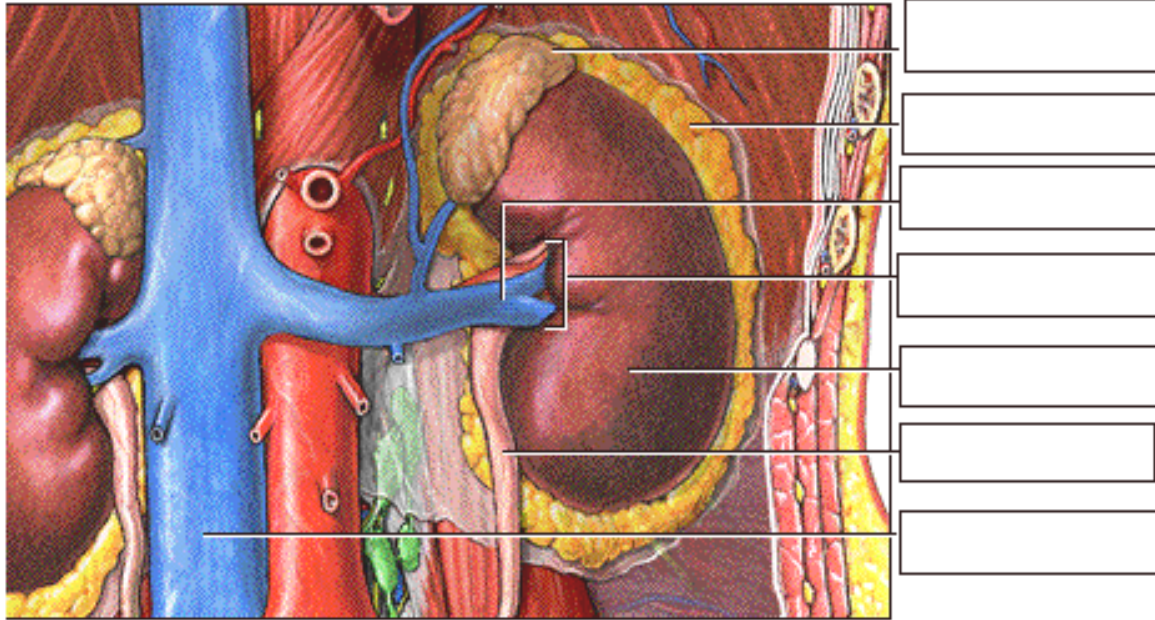
Page 3. The Urinary System

- The urinary system is composed of paired kidneys and ureters, the urinary bladder, and the urethra.
- Urine is produced in the kidneys, and then drains through the ureters to the urinary bladder, where the urine is stored. Urine is eliminated from the body through the urethra.
- Label this diagram:



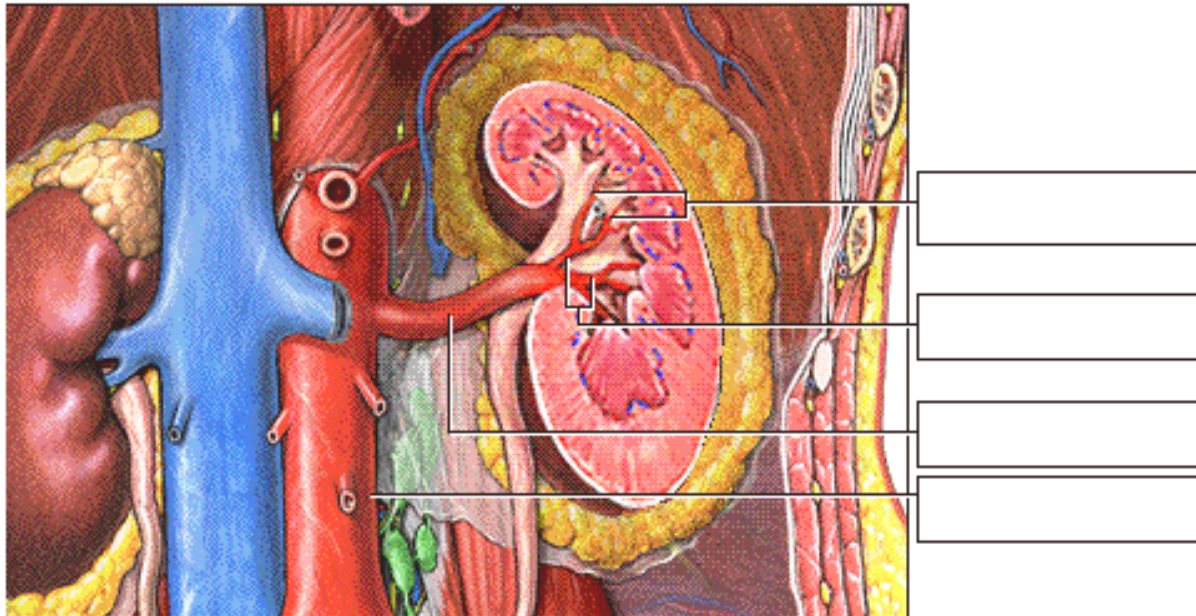
Page 4. External Structure of the Kidneys

- Each bean-shaped kidney is embedded in a fatty adipose capsule.
- The kidneys are retroperitoneal, lying against the dorsal body wall in the upper abdomen.
- An adrenal gland, which is part of the endocrine system, lies on top of each kidney.
- Several structures enter or exit the concave surface of the kidney at the renal hilum, including the ureter and the renal vein, which drains into the inferior vena cava.
- Label this diagram:



Page 5. Blood Supply of the Kidneys

- When the renal vein is removed and the kidney is shown in frontal section, you can see the deeper renal artery and its connection to the abdominal aorta.
- Branching from the renal artery are the segmental and lobar arteries.
- Together, these vessels provide the kidneys with a rich blood supply under high pressure that allows them to continuously filter and cleanse the blood.
- Label this diagram:



Page 6. Internal Structure of the Kidney

- Internally, the human kidney is composed of three distinct regions:
 1. **Renal Cortex**

- The outermost layer is called the renal cortex. It contains about one million nephrons, the filtering units that form urine.
- Types of Nephrons:
 - Cortical nephrons - lie completely within the cortex
 - Juxtamedullary nephrons - lie in both the cortex and medulla

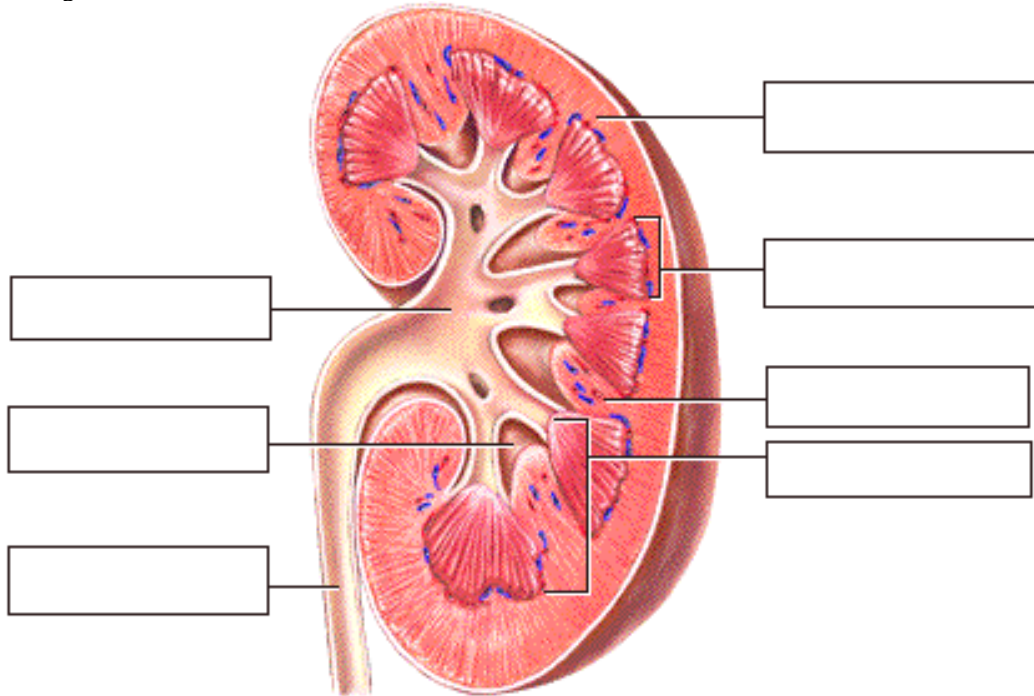
2. Renal Medulla

- The middle layer is called the renal medulla, in which you can see the triangular renal pyramids. These pyramids look striated because of parallel bundles of ducts carrying urine from the nephrons.
- The areas between pyramids are the renal columns. They are extensions of the cortex that provide a route for the passage of blood vessels and nerves to and from the outer cortex.

3. Renal Pelvis

- The funnel-shaped renal pelvis is within the renal sinus. The renal pelvis collects urine from the pyramids and conveys it into the ureter for passage to the urinary bladder.

- Label this diagram:



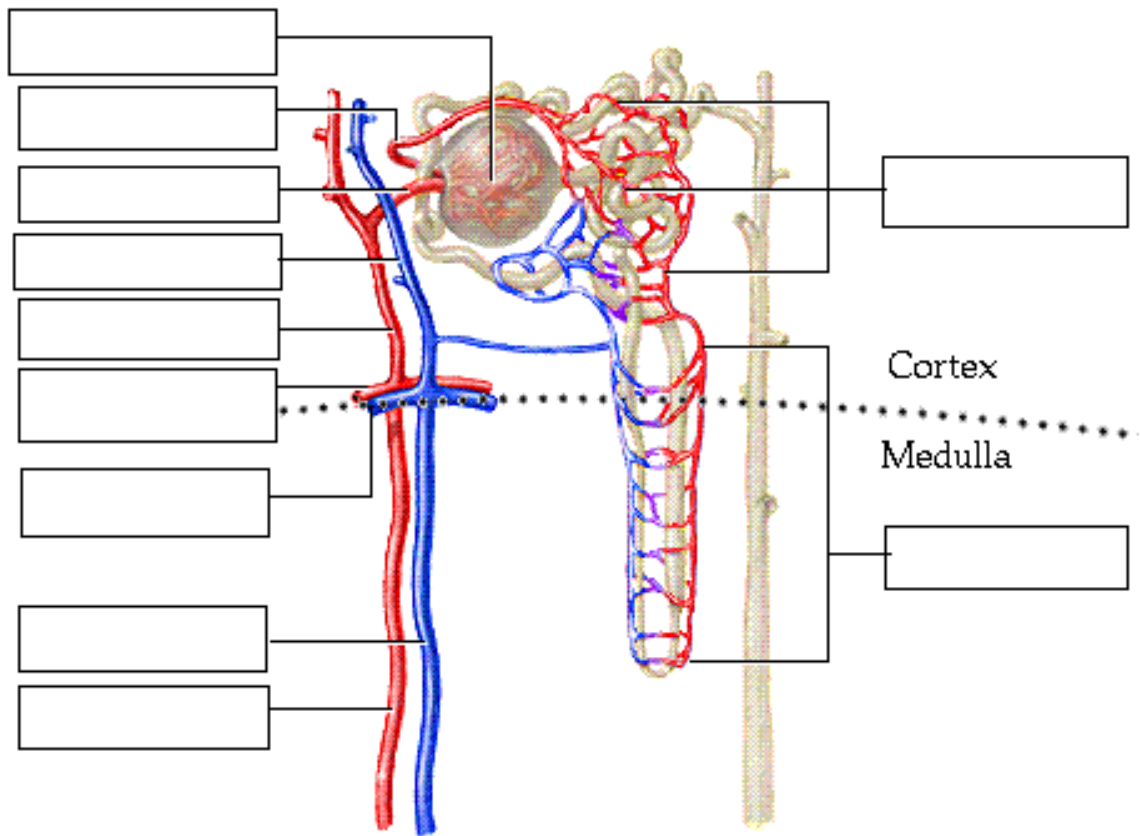
Page 7. Nephron Overview

- The nephron is the structural and functional unit of the kidneys. It consists of a specialized tubular structure and closely associated blood vessels.

Page 8. Nephron Structure: Associated Blood Vessels

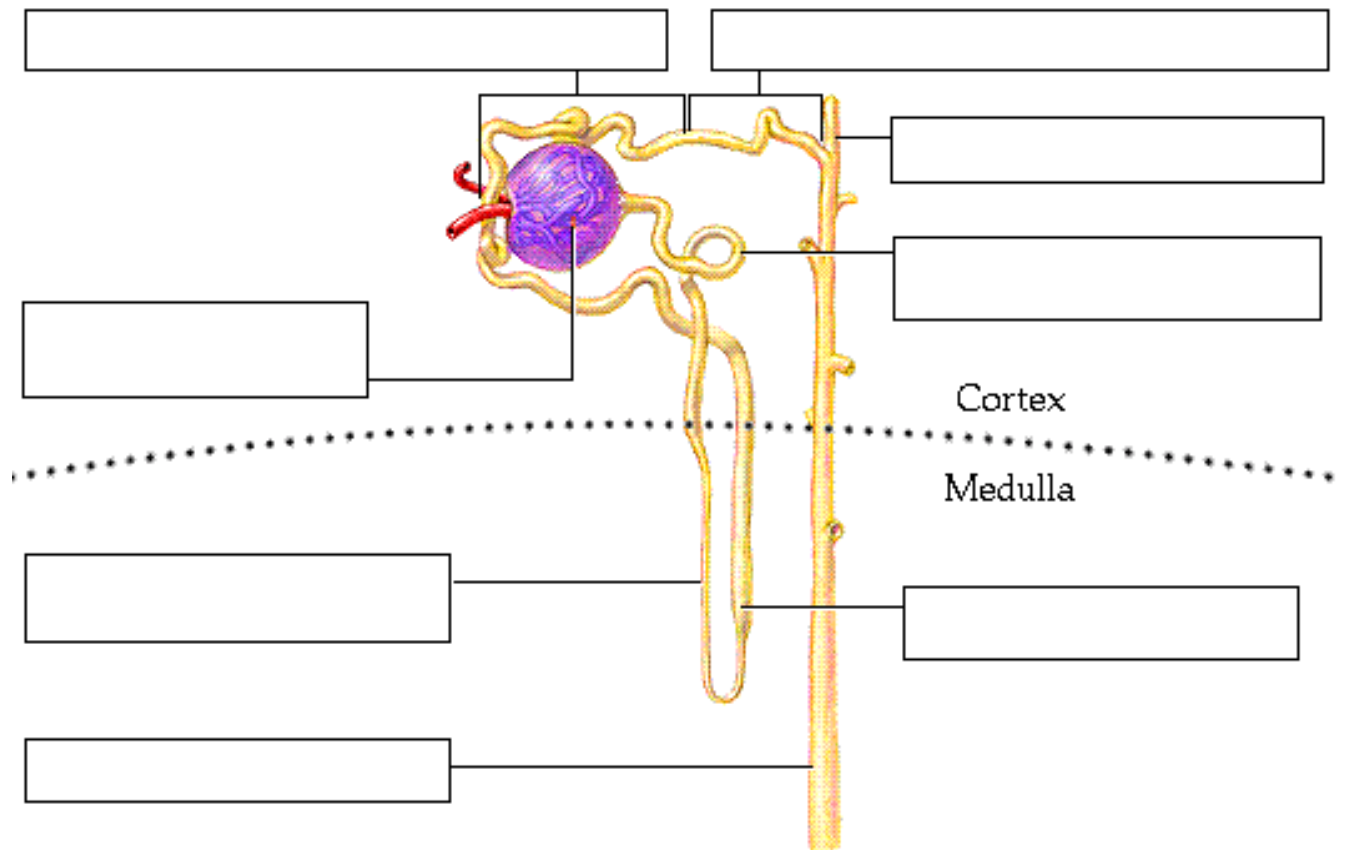
- Blood entering the kidney through the renal artery flows first into the segmental arteries and then into the lobar arteries.
- From there, it enters the interlobar arteries, the arcuate arteries, the small interlobular arteries, and the still smaller afferent arterioles, which empty into a capillary bed called the glomerulus.
- Leading away from the glomerulus is the efferent arteriole. Notice that the afferent arteriole is larger in diameter than the efferent arteriole.
- Blood passes from the efferent arteriole into the peritubular capillaries and vasa recta.
- From there, blood drains into the interlobular vein, flows into the arcuate vein and enters the interlobar vein, eventually reaching the renal vein.

- Label this diagram:



Page 9. Nephron Structure: Tubular Segments

- Label this diagram:



- The expanded 'cup-shaped' end of the tubule surrounding the glomerulus is called the glomerular, or Bowman's, capsule.

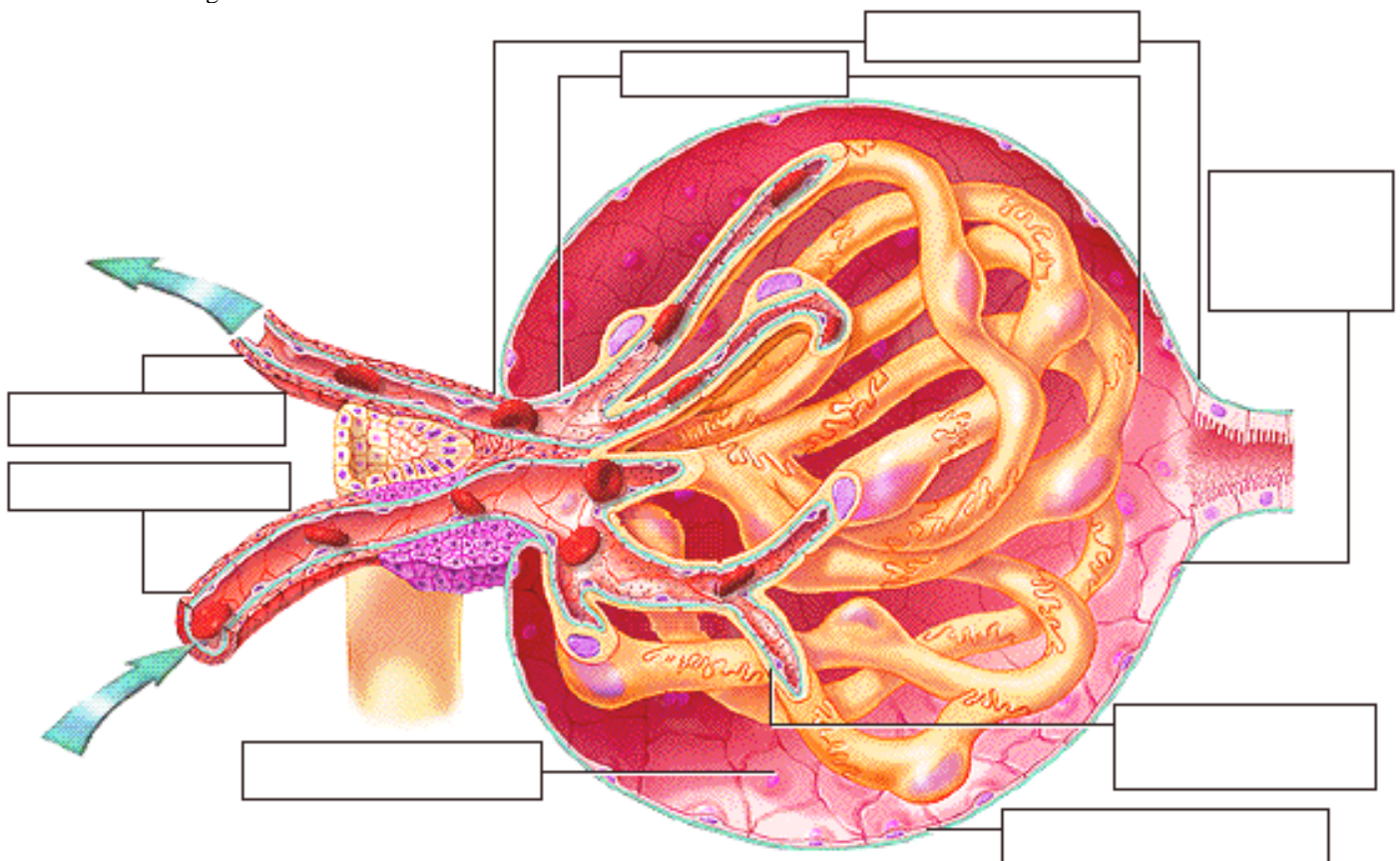
- Water and solutes pass from the blood into the glomerular capsule, and then flow into the proximal convoluted tubule, or PCT.
- After many loops and convolutions, the tubule straightens out, and fluid flows down the descending, or thin, segment of the loop of Henle into the medullary region, and then up the ascending, or thick, segment back into the cortical region.
- From the loop of Henle, the fluid then enters the twists and turns of the early and late distal convoluted tubule, or DCT, eventually emptying into a cortical collecting duct.
- This duct extends into the medulla, forming the medullary collecting duct, which carries the urine through the tubules of the renal pyramids to the renal pelvis.

** Now is a good time to go to quiz questions 1-4:

- Click the Quiz button on the left side of the screen.
- Work through questions 1-4.
- After answering question 4, click the Back to Topic button on the left side of the screen
- To get back to where you left off, click on the scrolling page list at the top of the screen and choose "10. Cellular Features of the Renal Corpuscle".

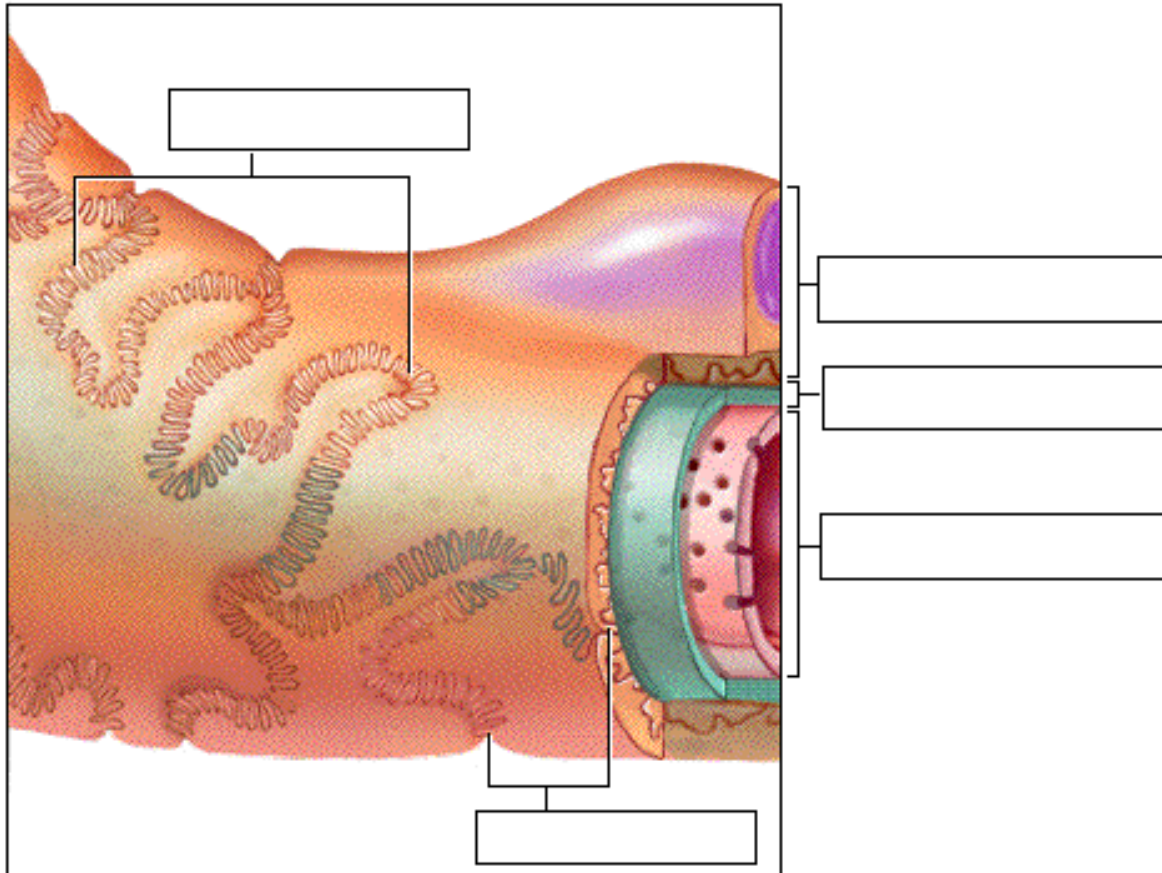
Page 10. Cellular Features of the Renal Corpuscle

- The glomerulus, with its larger incoming afferent arteriole and smaller outgoing efferent arteriole, is nested within the glomerular capsule something like a fist thrust into a balloon. Together, these structures are called the renal corpuscle.
- The visceral layer of the glomerular capsule is made up of specialized cells called podocytes, which surround the permeable capillaries.
- Between the visceral and parietal layers of the capsule lies the capsular space, which collects the fluid and solutes being filtered from the blood.
- Label this diagram:

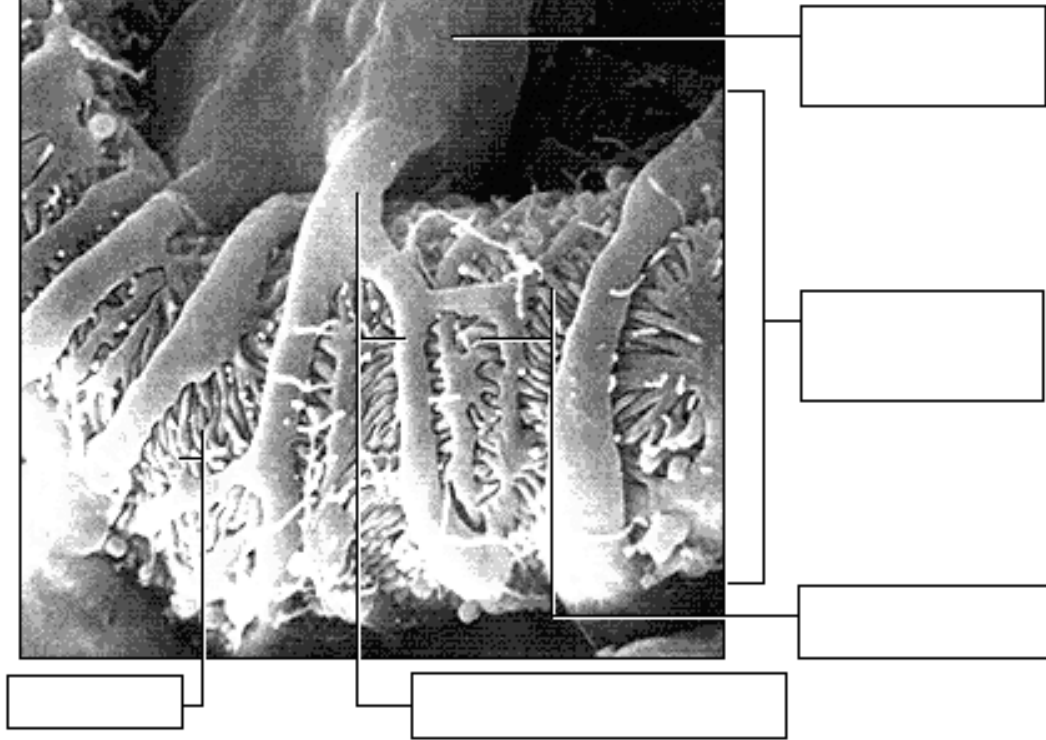
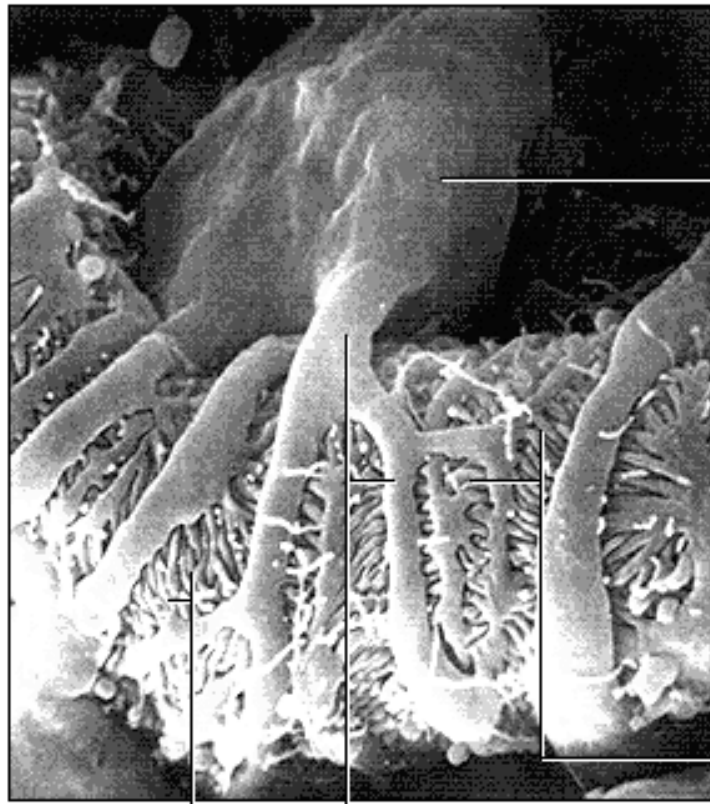


- In longitudinal section, the endothelial lining shows small openings called fenestrations, which allow for the passage of water and solutes such as ions and small molecules.
- There are fenestrations between endothelial cells in the capillary.
- The porous basement membrane encloses the capillary endothelium.
- Surrounding the basement membrane is a layer of podocytes. These cells have large 'leg-like' extensions, which in turn have small 'fringe-like' extensions called pedicels.

- Pedicels from adjacent areas interdigitate loosely to form spaces called filtration slits.
- Substances being filtered must pass first through the fenestrations, then through the basement membrane, and finally through the filtration slits and into the capsular space.
- Together, the capillary endothelium, basement membrane, and podocytes make up the filtration membrane.
- Label this diagram:

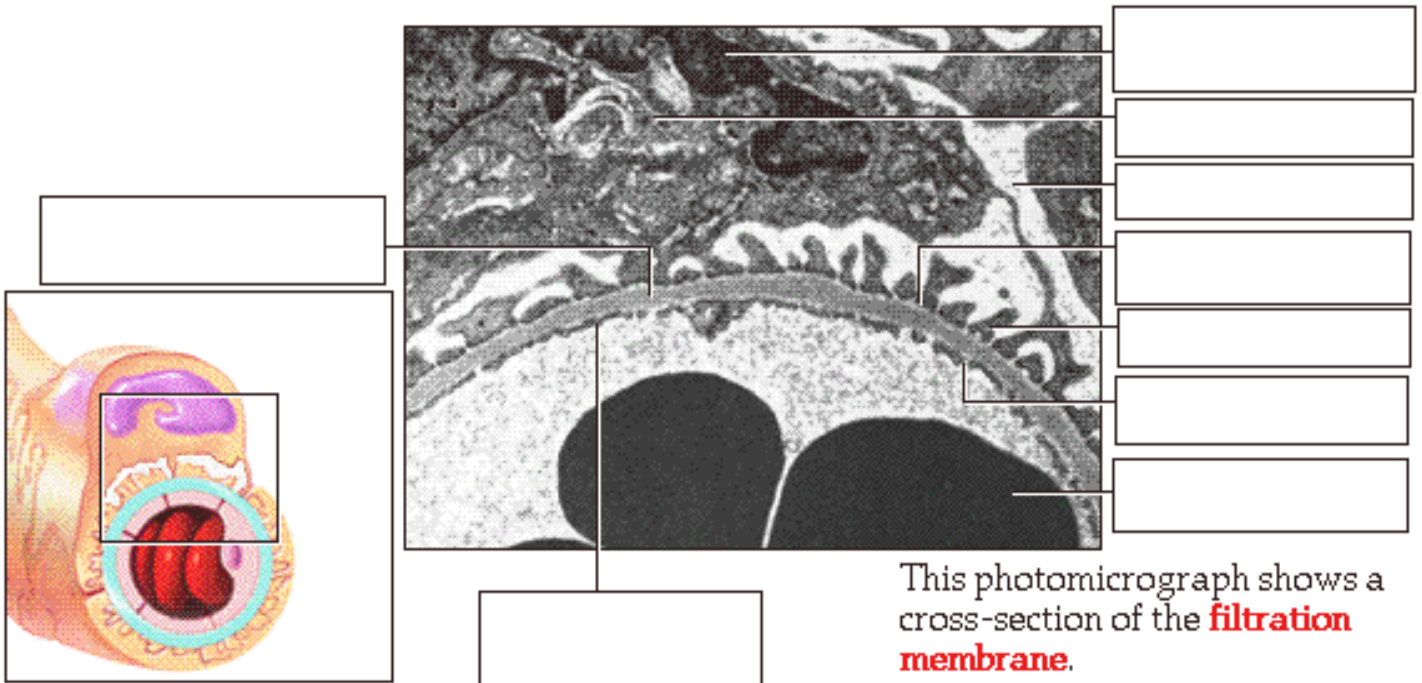


- Extending from the podocyte cell body are leg-like extensions containing the fringe-like pedicels. The extensions and pedicels wrap around the capillary and interdigitate to form the filtration slits.
- Label the diagram on the top of the next page:



Page 11. Structure of the Filtration Membrane in Cross Section

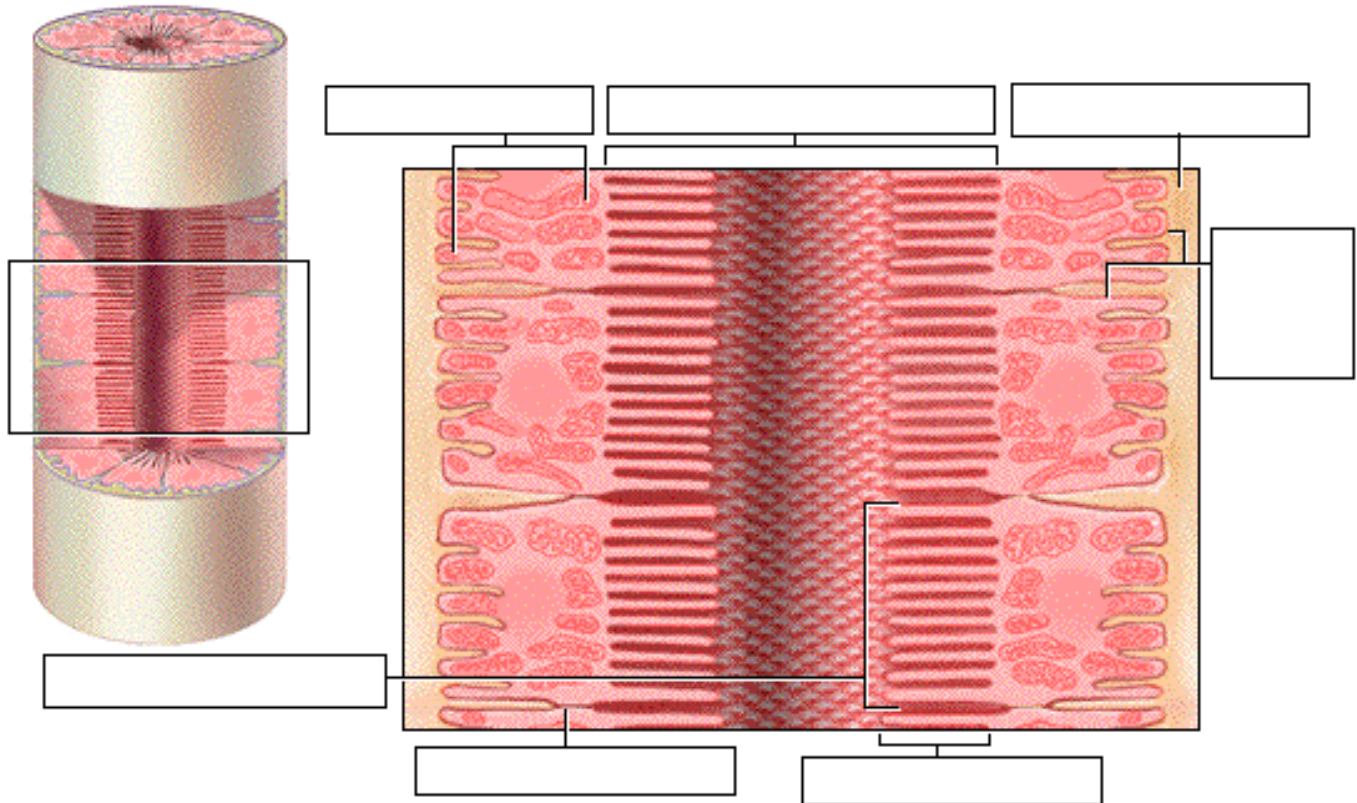
- A cross section of the filtration membrane reveals a large podocyte with its nucleus and pedicels. The white areas are portions of the capsular space. Gaps between the pedicels are the filtration slits.
- The basement membrane of the capillary endothelium separates the podocyte from the capillary with its fenestrations.
- Label this diagram:



- Notice that the filtration membrane permits the escape of small molecules, while preventing large molecules from leaving the bloodstream and passing through into the capsular space.

Page 12. Cells of the Proximal Convolved Tubule (PCT)

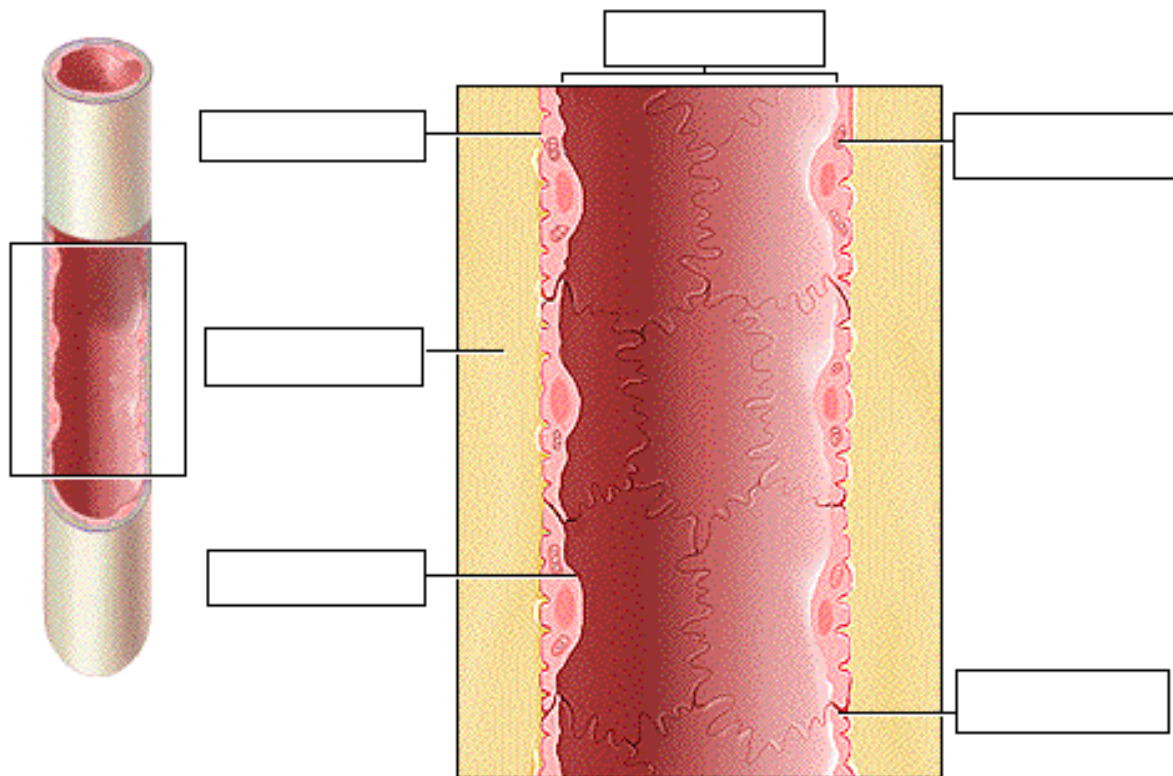
- Label this diagram:



- The simple cuboidal cells of the proximal convoluted tubule are called brush border cells because of their numerous microvilli, which project into the lumen of the tubule.
- These microvilli greatly expand the surface area of the luminal membrane, adapting it well for the process of reabsorption.
- Tight junctions between adjacent cells permit passage of water but limit the escape of large molecules from the tubular lumen into the interstitial space.
- The highly folded basolateral membrane of the cells contains numerous integral proteins involved in passive or active transport of substances between the intracellular and interstitial spaces. Numerous mitochondria provide the ATP necessary for these active transport processes.
- The key feature of these cells is that they are highly permeable to water and many solutes.

Page 13. Cells of the Thin Loop of Henle

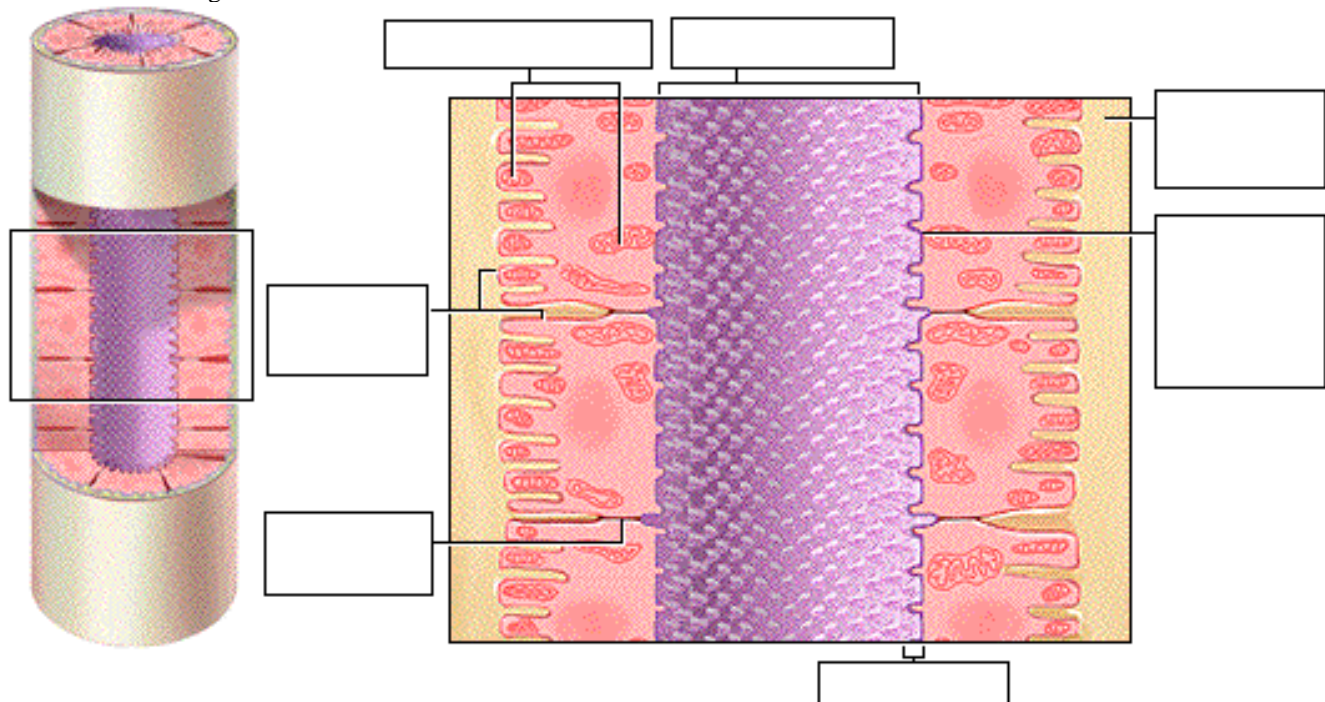
- The cells of the thin segment of the descending loop of Henle are simple squamous epithelial cells.
- These cells lack brush borders, which reduces their surface area for reabsorption.
- These cells continue to be permeable to water, they possess relatively few integral proteins that function as active transport molecules for reabsorbing solutes from the filtrate.
- The key feature of these cells is that they are highly permeable to water but not to solutes.
- Label this diagram:



Page 14. Cells of the Thick Ascending Loop of Henle and Early DCT

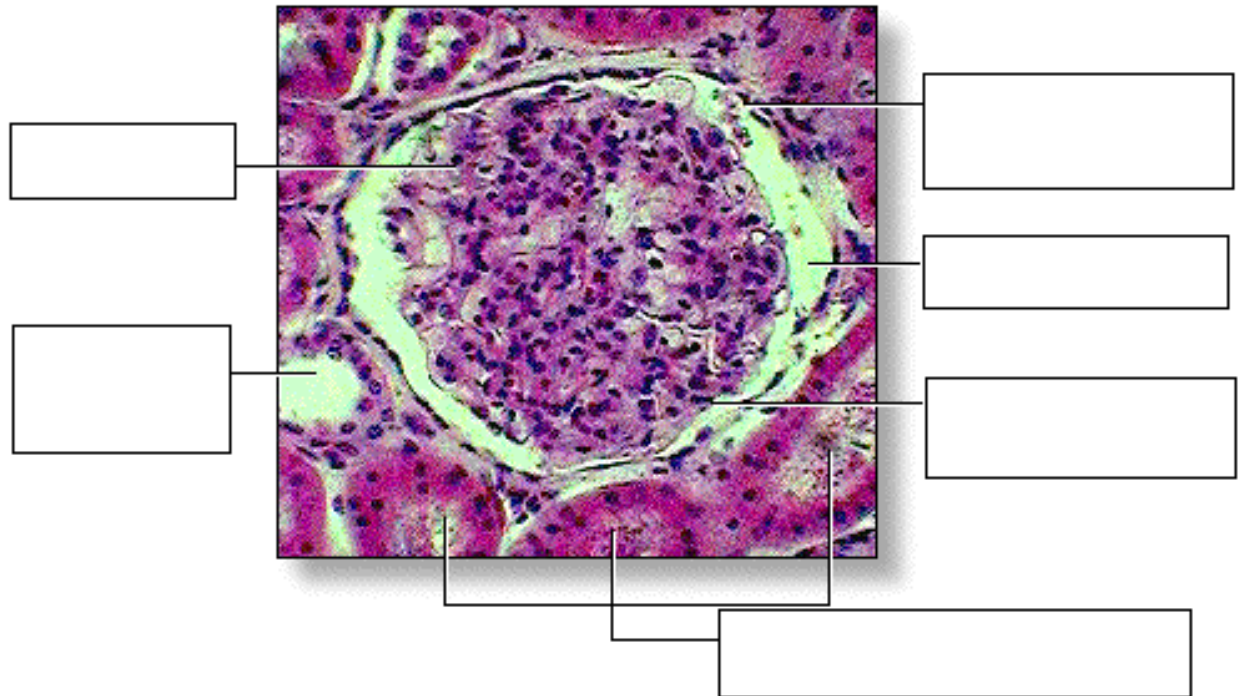
- The epithelia of the thick ascending loop of Henle and the early distal convoluted tubule are similar. They are composed of cuboidal cells, but they have several structural differences compared to the cells of the proximal convoluted tubule. For example, these cells have fewer and smaller microvilli projecting into the lumen.
- In addition, the luminal membrane is covered by a glycoprotein layer, which, along with 'tighter' tight junctions, greatly restricts the diffusion of water.
- The basolateral membrane is similar to that of the PCT, containing many integral proteins and closely associated mitochondria for passive and active membrane transport processes.
- The key feature of these cells is that they are highly permeable to solutes, particularly sodium chloride, but not to water.

• Label this diagram:



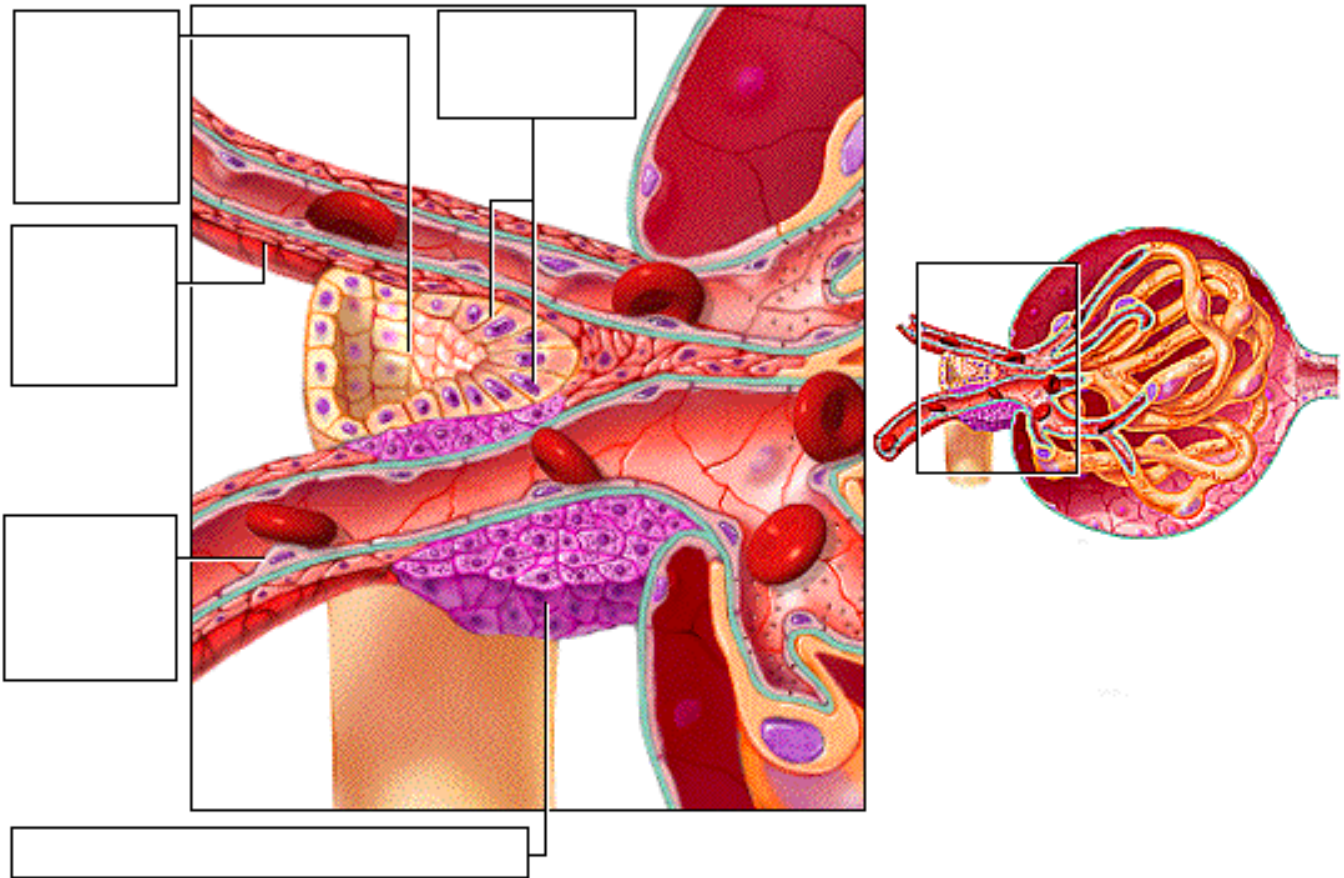
Page 15. Photomicrograph of Glomerulus and Adjacent Tubules

- This photomicrograph shows a cross section of a glomerulus surrounded by a glomerular capsule. It also shows several proximal convoluted tubules and a single distal convoluted tubule.
- The microvilli in the lumen of the proximal convoluted tubules appear fuzzy because they do not stand up well to the slide preparation process.
- Notice the much clearer, open lumen of the DCT, which is less obstructed because it has fewer microvilli.
- Label this diagram:



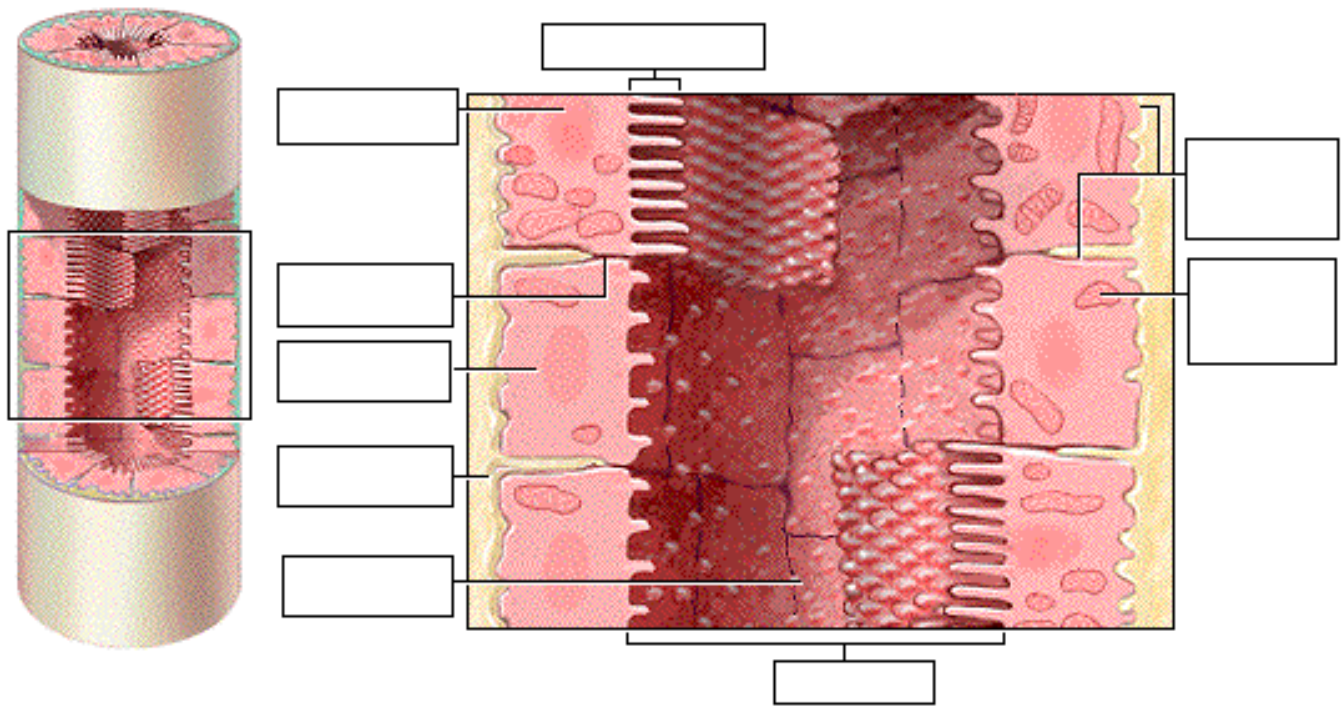
Page 16. The Juxtaglomerular Apparatus

- As the thick ascending loop of Henle transitions into the early distal convoluted tubule, the tubule runs adjacent to the afferent and efferent arterioles.
- Where the cells of the arterioles and of the thick ascending loop of Henle are in contact with each other, they form the monitoring structure called the juxtaglomerular apparatus.
- The modified smooth muscle cells of the arterioles (mainly the afferent arteriole) in this area are called juxtaglomerular or JG cells. These enlarged cells serve as baroreceptors sensitive to blood pressure within the arterioles.
- Cells of the thick ascending segment in contact with the arterioles form the macula densa. These cells monitor and respond to changes in the osmolarity of the filtrate in the tubule.
- Label this diagram:



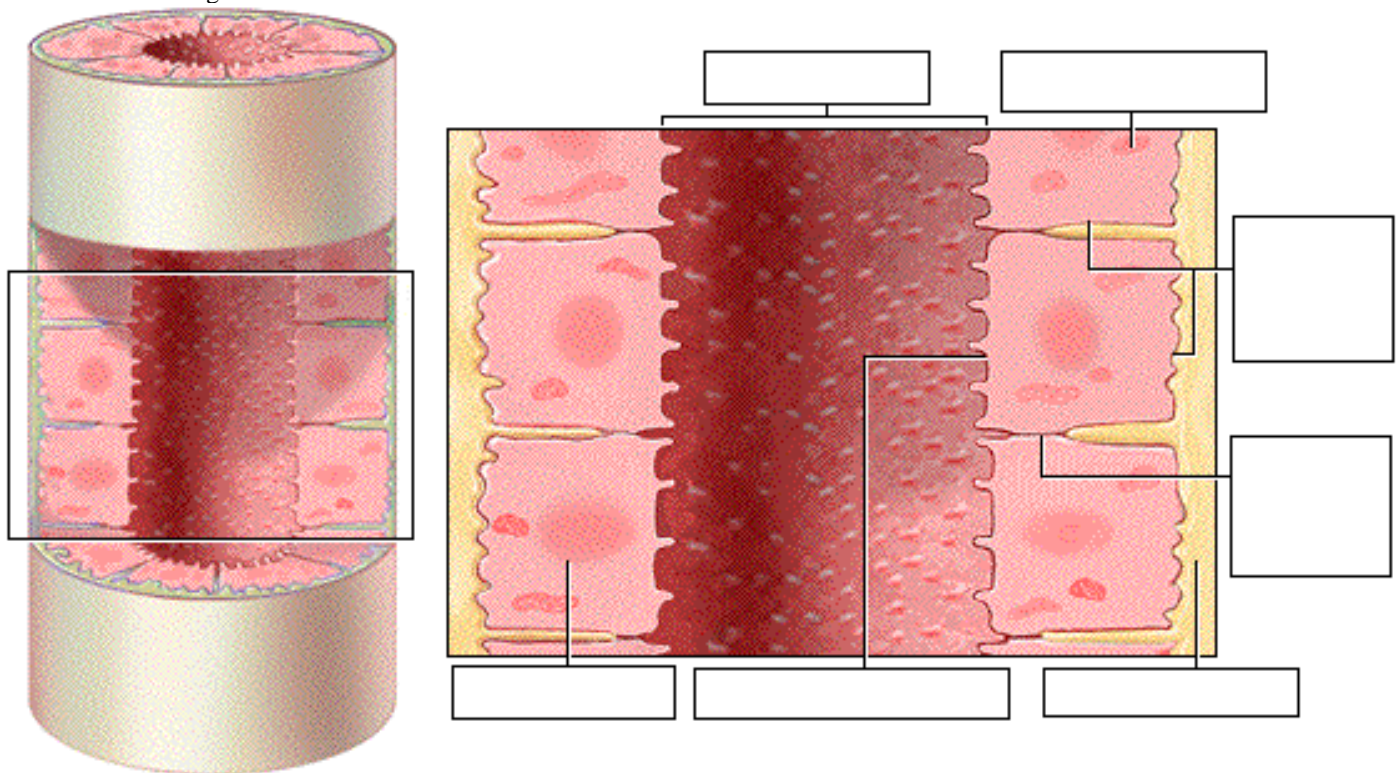
Page 17. Cells of the Late DCT and Cortical Collecting Duct

- The cuboidal cells of the late distal convoluted tubule and the cortical collecting duct fall into two distinct structural and functional types: principal cells and intercalated cells.
 1. **Principal Cells** The more numerous principal cells have few microvilli and basolateral folds. These specialized cells respond to certain hormones that regulate the cell's permeability to water and solutes, specifically sodium and potassium ions. The key feature of principal cells is that their permeability to water and solutes is physiologically regulated by hormones.
 2. **Intercalated Cells** When the acidity of the body increases, the intercalated cells secrete hydrogen ions into the urine to restore the acid/base balance of the body. The key feature of intercalated cells is their secretion of hydrogen ions for acid/base balancing.
- Label this diagram:



Page 18. Cells of the Medullary Collecting Duct

- Principal cells of the medullary collecting duct are mostly cuboidal in shape. The luminal and basolateral membranes are relatively smooth, and the cells possess few mitochondria. The permeability of these cells to water and urea is hormonally regulated as the fluid passes through this region.
- The key feature of these cells is their hormonally regulated permeability to water and urea.
- Label this diagram:



Page 19. Photomicrographs of Collecting Ducts

- In photomicrographs of a longitudinal section and a cross section of collecting ducts, one will notice that the ducts are composed of cuboidal cells. The lumen of the collecting duct, shown in cross section, is much larger than the lumens of

the adjacent thick ascending tubules. This reflects the volume of fluid the collecting ducts contain as they gather the fluid from many nephrons.

Page 20. Summary

- The urinary system is composed of the kidneys, ureters, bladder, and urethra.
- The kidney is composed of three regions: the renal cortex, medulla, and pelvis.
- The functional unit of the kidney, the nephron, is composed of a tubular portion and associated blood vessels.
- Each region of the tubular portion of the nephron depends on the unique features of its epithelial cells to carry out its function.

****** Now is a good time to go to quiz questions 5-6:

- Click the Quiz button on the left side of the screen.
- Click on the scrolling page list at the top of the screen and choose "5. Tubular Cell Types".
- Work through quiz questions 5-6.

Notes on Quiz Questions:

Quiz Question #1: Structures of the Renal System

- This question asks you to label the parts of the urinary system and the blood vessels associated with the kidney.

Quiz Question #2: Structures of the Kidney

- This question asks you to label the parts of the kidney.

Quiz Question #3: Tubular Structure of the Nephron

- This question asks you to assemble the parts of the nephron.

Quiz Question #4: Label the Nephron

- This question asks you to label the parts of the nephron.

Quiz Question #5: Tubular Cell Types

- This question asks you to identify the cell types in each region of the nephron.

Quiz Question #6: Tubular Definitions

- This question asks you to match the location of cell in the nephron to its characteristics.

Study Questions on Anatomy Review: Urinary System:

1. (Page 1.) What are two functions of the urinary system?
2. (Page 3.) Match the following parts of the urinary system to their function:

Ureter	a. Where urine is produced.
Kidney	b. Urine is stored here.
Urethra	c. Brings urine from the kidneys to the bladder.
Urinary bladder	d. Urine is eliminated from the body through this tube.
3. (Page 3.) Label the diagram of the urinary system on page 3.
4. (Page 4.) What is the name of the fatty tissue that lies around each kidney?
5. (Page 4.) What is the name of the endocrine gland that lies on top of each kidney?
6. (Page 4,5.) What is the name of three structures that enter or exit the concave surface of the kidney at the renal hilus?
7. (Page 4.) Label the diagram of the kidney on page 4.
8. (Page 5.) Label the diagram of the kidney on page 5.
9. (Page 6.) About how many nephrons are there in each kidney?
10. (Page 6.) What is the function of the nephrons?
11. (Page 6.) What are the two types of nephrons and where are each located?

12. (Page 6.) Why do the renal pyramids look striated?
13. (Page 6.) What are the areas between the renal pyramids called and what is their function?
14. (Page 6.) What is the function of the renal pelvis?
15. (Page 6.) Label the diagram on p. 6.
16. (Page 8.) Trace the pathway of blood to and from a nephron, by listing the following blood vessels in order:

peritubular capillaries	interlobular arteries	renal artery	arcuate vein
glomerulus	interlobular vein	afferent arterioles	vasa recta
segmental arteries	interlobar vein	renal vein	lobar arteries
arcuate arteries	efferent arteriole	interlobar arteries	
17. (Page 8.) Which is larger in diameter, the afferent or efferent arteriole?
18. (Page 8.) Label the diagram on p. 8.
19. (Page 9.) Trace the pathway of forming urine within the juxtamedullary nephron by placing the following structures in order:

early distal convoluted tubule (DCT)	cortical collecting duct
descending loop of Henle	proximal convoluted tubule (PCT)
Glomerular capsule (Bowman's capsule)	ascending loop of Henle
medullary collecting duct	late distal convoluted tubule (DCT),
20. (Page 8.) Label the diagram on p. 9.
21. (Page 10.) Label the first diagram on page 10.
22. (Page 10.) What is the renal corpuscle made of?
23. (Page 10.) What are the two layers of the glomerular (Bowman's) capsule called?
24. (Page 10.) What is the visceral layer of the glomerular capsule made of?
25. (Page 10.) What is between the visceral and parietal layers of the glomerular (Bowman's) capsule?
26. (Page 10.) What is the function of the capsular space?
27. (Page 10.) Label the second diagram on page 10.
28. (Page 10.) Match the openings to their location:

fenestrations	a. basement membrane
filtration slits	b. podocytes
porous structure	c. endothelium of glomerular capillary
29. (Page 10.) What are the small 'fringe-like' extensions on podocytes called?
30. (Page 10.) What are the spaces between pedicels called?
31. (Page 10.) When a substance is being filtered from the blood in the capsular space into the capsular space, what does it have to pass through, from first to last?
32. (Page 10.) What does the term "filtration membrane" refer to?
33. (Page 10.) Label the third diagram on page 10.
34. (Page 11.) Label the diagram on page 11.
35. (Page 11.) Does the filtration allow both small and large molecules to pass through?
36. (Page 10.) What cell type makes up the parietal layer of the glomerular (Bowman's) capsule?
37. (Page 12.) Label the diagram on page 12.
38. (Page 12.) What cell type lines the proximal convoluted tubules?
39. (Page 12.) What is another name for the apical side of the cells lining the PCT? What is present on the apical side of the cells lining the PCT? What is its function?
40. (Page 12.) What is the function of the tight junctions between adjacent cells in the PCT?

41. (Page 12.) What is the basal and lateral sides of the cells in the PCT called?
42. (Page 12.) What is present in the basolateral membrane of PCT cells?
43. (Page 13.) What cell type lines the thin descending loop of Henle?
44. (Pages 12-14, 17-18.) Match the cell types to their key feature:
 1. Cells of the thick ascending loop of Henle and the early distal convoluted tubule
 2. Intercalated cells of the late DCT and Cortical Collecting Duct
 3. Cells of Proximal Convoluted Tubule
 4. Principal cells of the late DCT and Cortical Collecting Duct
 5. Cells of the Thin Loop of Henle
 6. Cells of the medullary collecting duct
 - a. secretion of hydrogen ions for acid/base balancing
 - b. their permeability to water and solutes is regulated by hormones
 - c. highly permeable to water but not to solutes
 - d. hormonally regulated permeability to water and urea
 - e. highly permeable to solutes but not to water
 - f. highly permeable to water and many solutes
45. (Page 13.) Label the diagram on p. 13.
46. (Page 14.) Label the diagram on p. 14.
47. (Page 14.) What type of tissue is present in the thick ascending loop of Henle and the early DCT?
48. (Page 14.) What features of cells in the thick ascending loop of Henle and early DCT make this membrane highly permeable to solutes, but not water?
49. (Page 15.) Label the diagram on p. 15.
50. (Page 16.) Label the diagram on p. 16.
51. (Page 16.) Where is the juxtaglomerular apparatus?
52. (Page 16.) What are the names of the two cell types present in the juxtaglomerular apparatus and what are they a part of? What are they responsive to?
53. (Page 17.) Label the diagram on p. 17.
54. (Page 17.) What two cell types are found in the late DCT and cortical collecting duct? Which are more numerous?
55. (Page 17.) What tissue type are the cells of the late DCT and cortical collecting duct?
56. (Page 18.) Label the diagram on p. 18.
57. (Page 18.) What cell type is found in the medullary collecting duct?